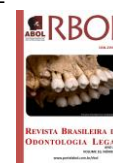

Revista Brasileira de Odontologia Legal – RBOL

ISSN 2359-3466

<http://www.portalabol.com.br/rbol>



Forensic dentistry

HYALURONIC ACID LIP AUGMENTATION AND ITS EFFECT ON HUMAN IDENTIFICATION BY CHEILOSCOPY: A CASE REPORT.

Preenchimento labial com ácido hialurônico e suas implicações na identificação humana através da queilosscopia: relato de caso.

Daline Oliveira CARNEIRO¹, Gardenia Carvalho Santos FERNANDES², Jamilly de Oliveira MUSSE³, Jeidson Antônio Morais MARQUES⁴.

1. PhD student in the Postgraduate Program in Dentistry and Health at the Federal University of Bahia (UFBA), Salvador – BA, Brazil
2. Dentist graduated from the Feira de Santana Teaching Unit (UNEF), Feira de Santana – BA, Brazil.
3. Titular Professor at the State University of Feira de Santana (UEFS), Feira de Santana - BA; Forensic Odontologist at the Technical Police Department/BA, Brazil
4. Titular Professor at the State University of Feira de Santana (UEFS), Feira de Santana – BA, Brazil

Information about the manuscript:

Received: November 6, 2023
Accepted: January 5, 2024

Contact author:

Daline Oliveira Carneiro
Universidade Federal da Bahia – Faculdade de Odontologia. Av. Araújo Pinho, 62, Canela – Salvador, Bahia, Brazil. Postal code: 40110-150
E-mail: dalineoliveira@hotmail.com.

ABSTRACT

Cheiloscopy is a human identification technique that consists of studying the lips and their characteristics, such as their thickness, the arrangement of the labial commissure, the position of the grooves and their classifications, as well as recording the impressions produced by them on various supports. Lip augmentation with hyaluronic acid (HA) fillers has become very popular in recent years, especially since facial harmonization was included as a dental specialty. The aim of this study was to verify whether lip fillers with HA have implications for cheiloscopic studies, by means of a clinical case report. A 37-year-old female patient with leukoderma took part in the study. Photographs were taken and measurements of lip thickness, lip commissure layout and lipstick impressions were taken before the lip filler, 15 days after the application of 1 ml of HA and 15 days after the full 2 ml of HA filler. The results of the study suggest that lip filling with HA can interfere with the cheiloscopic method, as there was a change in the architecture of the lips, the layout of the labial commissure, improved contour, cupid's bow and filter, with a significant change in the thickness of the upper and lower lips of approximately 42% in relation to the previous volume. As for the pattern of the lip furrows, there was no change in the designs, however, the quality of the lip impression was affected due to the effect produced by the HA.

KEYWORDS

Forensic dentistry; Hyaluronic Acid; Lip.

INTRODUCTION

Dental forensic identification can be established by combining scientific methods that make the identification process secure. The Forensic Dentist can therefore use

cheiloscopy as an additional tool in criminal investigations^{1,2}. This technique consists of studying the lips and their characteristics, such as their thickness, the arrangement of the labial commissure, the position of the

grooves and their classifications, as well as recording the impressions produced by them on a given substrate³.

The biological characteristics of human lips were first described by Fisher in 1902. In 1930, through the studies of Diou de Lille, the lip grooves and their impressions were considered useful in criminology. Two years later, Edmond Locard, known as the "father of criminology", recognized the importance of cheiloscropy. It wasn't until 1950 that the concept of human identification using lip furrow impressions was suggested by Le Moyne Snyder^{3,4}. Since then, many classification methods have been developed to establish this technique as evidence for human identification. However, in 2013, the methodology proposed by Suzuki and Tsuchihashi (1974) was recognized as a standard system by the National Standard Institute/National Institute of Standards and Technology (ANSI/NIST) revised by the IFL-1-2011 dental standard^{2,5}.

The anatomy of the labial folds is of a permanent and unalterable nature. Its formation begins in the 6th week of intrauterine life and rarely undergoes alterations, resisting many aggressions intact, including herpetic lesions. However, the cheiloscopy method can be unfeasible in cases of scars left by burns or surgery⁴.

Although the design of these prints is immutable, their use as an identification technique is more significant in criminal investigations, in the comparison of recent prints, visible or latent, left on objects or belongings at the scene of crimes, because due to the changes that these prints can

undergo with aging, this method presents classification difficulties to be used as a standardized identification method⁶.

The lips play an important role in the aesthetic perception of the face, their definition and size providing connotations of youth, sensuality and beauty⁷. With the ageing process, the upper lip loses muscle volume, and the connective tissues weaken, resulting in a less prominent philtrum, decreasing the vertical height of the lip and leading to its inversion in the oral cavity. These changes in volume, together with actinic and elastic changes, also produce perioral wrinkles⁸. Therefore, restoring this lost volume has been gaining ground in orofacial aesthetics and lip augmentation with hyaluronic acid (HA) dermal fillers has become very popular in recent years⁹.

HA is a polysaccharide, basically a glycosaminoglycan, formed from the repetition of disaccharide units of N-acetyl-D-glucosamine and D-glucuronic acid, and is naturally present in our bodies⁷. Lip filling with HA is a minimally invasive technique that consists of applying HA to the lips using a syringe in order to fill them. The filler restores fullness to the lips, restores lost contour and even reshapes specific points on the upper lip or both¹⁰. There is also a moisturizing effect, due to its ability to absorb water, which is beneficial for ageing tissue⁹.

It can be seen that lip thicknesses change as a result of this aesthetic procedure. Studies have shown that the application of HA to the lips leads to tissue maturation and confirm the ability of HA to reorganize and integrate the extracellular

matrix after 6 months¹¹. HA injection effectively increases lip fullness by up to 6 months and its effect can last up to 12 months among most treated patients¹².

In this sense, considering that lip filling with HA can influence the method of identification through cheiloscopy, the aim of this study was to evaluate the morphological characteristics of the lips before and after filling with HA and the implications of this procedure for odontolegal identification, in order to verify the reliability of the cheiloscopy method as a forensic tool.

CASE REPORT

A 37-year-old female patient with leukoderma, whose main complaint was the aesthetics of her lip. She reported low lip volume and dryness with the formation of perioral lines. On systemic assessment, the patient was in good health, with no history

of disease or trauma to the facial region, no lip scars or history of infection by the oral herpes simplex virus that would contraindicate the procedure. This study is a clinical case report in which the lip filling procedure was carried out with a total of 2 ml of HA. The volunteer in this study agreed to take part and signed a consent form for the use of her image and voice.

Data was collected at three different times: before the procedure, 15 days after the first filling session with 1 ml and 15 days after the second filling session with 1 ml of HA. The filling was divided into two stages, with an interval of 30 days between the sessions, in order to safely inject HA and avoid complications such as arterial embolism, venous occlusion and consequent tissue necrosis. We waited 15 days between injections due to the time needed for tissue repair and reduction of post-filling edema – Figure 1.

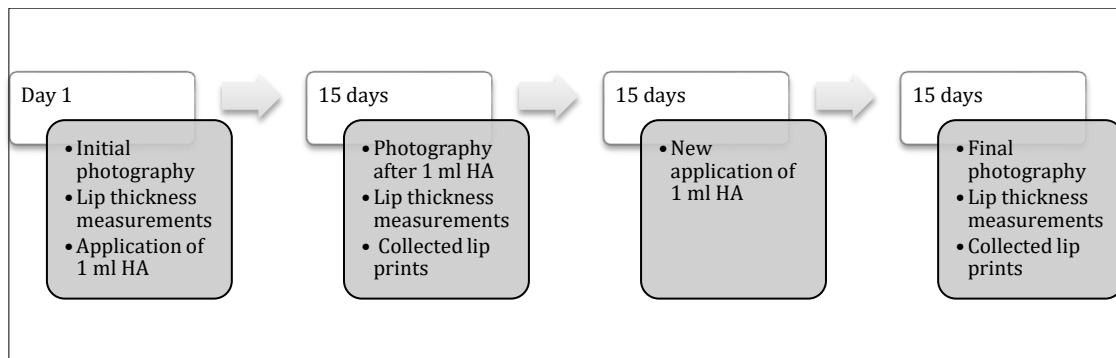


Figure 1. Data collection flowchart.

To analyze the results, measurements were taken of lip thickness, lip commissure layout and lipstick impressions before filling, after applying 1 ml of HA and after completing 2 ml of filling with HA.

Lip thickness measurements were taken using a compass with dry tips and a

millimeter ruler. The following anatomical points were used as reference points: the upper lip was measured with one end of the compass at its upper margin, at the level of the labial cord, and the other end of the instrument at the buccal rima, in the center of the sagittal midline; the lower lip was measured at the buccal rima and the lower

margin of the labial cord, based on the sagittal midline. Lip thickness was classified according to the study by Utsuno et al., 2005¹³:

- a) Thin or slender lips: the mucous membrane of the lip is barely visible, measuring less than 8 mm.
- b) Medium lips: larger area of visible lip mucosa, rounder lip vermilion region, with thickness varying between 8 and 10 mm.
- c) Thick or very thick lips: high amount of visible mucosa, thickness greater than 10 mm.
- d) Mixed lips: the classification of the upper component differs from the lower: the upper component is less thick than the lower or vice versa.

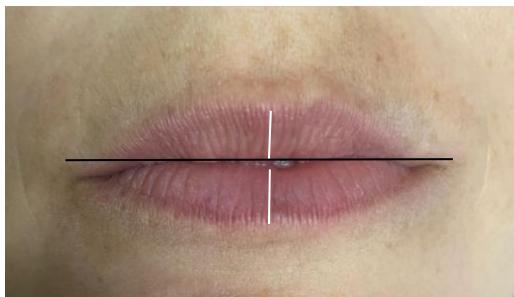


Figure 2. Initial photo of the case. Lip thickness measurements (white line). Collection of the labial commissure pattern (black line).

To analyze the pattern of the labial commissure, the participant was positioned with the Frankfurt plane parallel to the ground, with her lips sealed, and then two photographs were taken: one from a distance and the other close-up, using a high-resolution digital camera. The labial

commissures were classified using the photographs according to the criteria proposed by Santos (1967) cited by Barros et al. (2006)¹⁴, by taking their arrangement in relation to a line drawn perpendicular to the labial midline, tangent to the upper labial tubercle. According to this arrangement, the labial commissures are divided into three groups: raised, horizontal or lowered.

The impression of the lips was taken using an individual lipstick sample. After staining the entire lip volume, the lipstick was left to dry for approximately two minutes and then a lip impression was made on a white cardboard backed up by a glass plate. The impression was taken with the lips sealed and relaxed, pressed lightly in a rolling motion from left to right against the cardboard¹⁴. Transparent adhesive tape was used to protect the lip print and prevent traces from being lost.

Next, lip fillers with HA were applied by a suitably qualified professional. This aesthetic procedure was paid for by the research participant/volunteer.

All the impressions were analyzed using a magnifying glass or photographic magnification by a single examiner trained for the study. To analyze sulcular types, the lip impression was divided into four quadrants - upper right, upper left, lower left and lower right - and eight sub-quadrants. The sulcular types were classified based on the pattern of grooves obtained from the lip impression on cardboard, using the method proposed by Suzuki and Tsuchihashi (1974)¹⁵, shown in table 1.

Table 1. Classification by Suzuki and Tsuchihashi (1974)¹⁵.

LINE TYPE	SYMBOL	DESCRIPTION
Complete Vertical Line	I	Lip grooves that run vertically across the lip and cover its entire length.
Incomplete Vertical Line	I'	Vertical lip grooves that do not cover the entire length of the lip.
Bifurcated line	II	Lip grooves that branch or bifurcate along the path.
Intersecting Line	III	Lip grooves that intersect, adapting to the shape of a quotation mark.
Reticular Line	IV	Lip grooves that are organized producing various crossings, giving a net-like appearance.
Line with irregular pattern	V	These are labial grooves which, morphologically, are not included in any of the designations described above.

The facial analysis showed that the patient had thin lips with well-marked sulcular lines, a barely visible lip mucosa and dental exposure with relaxed lips. The mucocutaneous junction of the upper and lower lips, the area that ensures the contour of the lips, was not very evident. The lip filter and the area known as the cupid's bow were not well defined (Figure 2). The labial commissure was classified as lowered. After measuring the upper and lower lip thicknesses, it was possible to characterize them, according to their maximum width, as thin or thin lips, the measurement of which was less than 8 mm in both.

After the lip filling procedure with HA, there was an improvement in lip contour and volume, with a gain in projection. Lip thickness increased by 3 mm for each lip, the upper lip measured 9 mm and the lower lip measured 10 mm, being classified as medium lips with a larger area of visible mucosa compared to the previous situation. The vermilion region of the lip became rounder and projected forward, the cupid's bow was outlined and the filter was more prominent. The lip commissure has gained support, changing its position to the type classified as horizontal. The lips looked hydrated and the furrows were less evident (Figure 3).

The lip prints were compared using a magnifying glass and photographic magnification. Two impressions from each moment were used for better comparison. For all stages, the general shape of the drawing, number of grooves between two homologous points, coinciding points and accidental particularities were analyzed, considering the most prevalent type in each subquadrant, using the classification of Suzuki and Tsuchihashi (1974)¹⁵. Before the procedure, the predominant line types were the complete vertical line type and the bifurcated line type (Figure 4).

After filling, there was no change in the pattern of sulcular lines. However, some quadrants were classified as incomplete vertical lines at both times (Figures 5 and 6).

DISCUSSION

The results of this study showed that filling with HA caused changes in the architecture of the upper and lower lips, with alterations to the layout of the labial commissure, cupid's bow, philtrum and a significant change in lip thickness, with an increase of approximately 42% in relation to its previous volume.

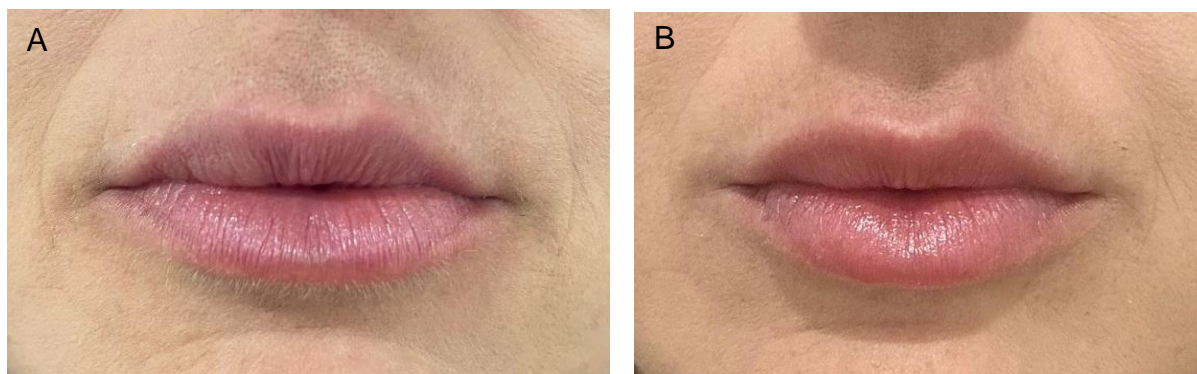


Figure 3. Final appearance 15 days after the first session of 1 ml of HA (A). Final appearance 15 days after the second session of 1 ml of HA (B).

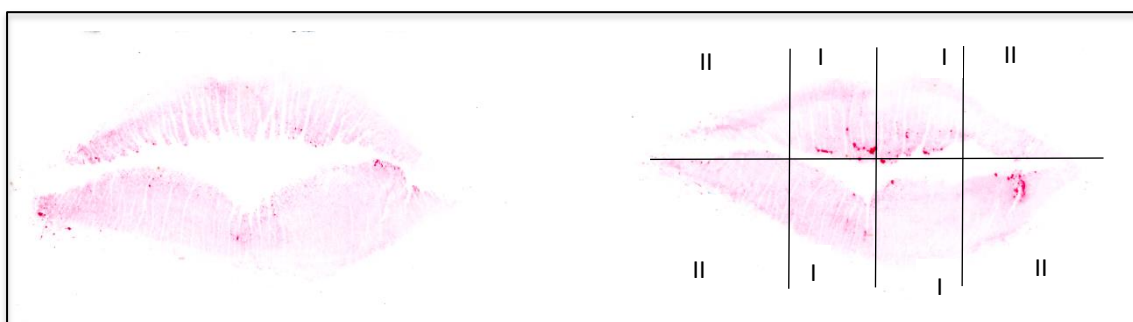


Figure 4. Lip impressions before filling with HA.

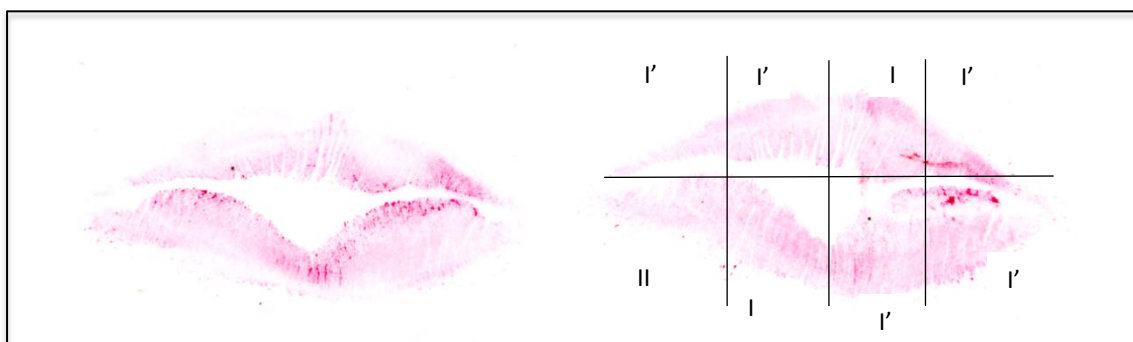


Figure 5. Lip impressions after the first HA filling session.

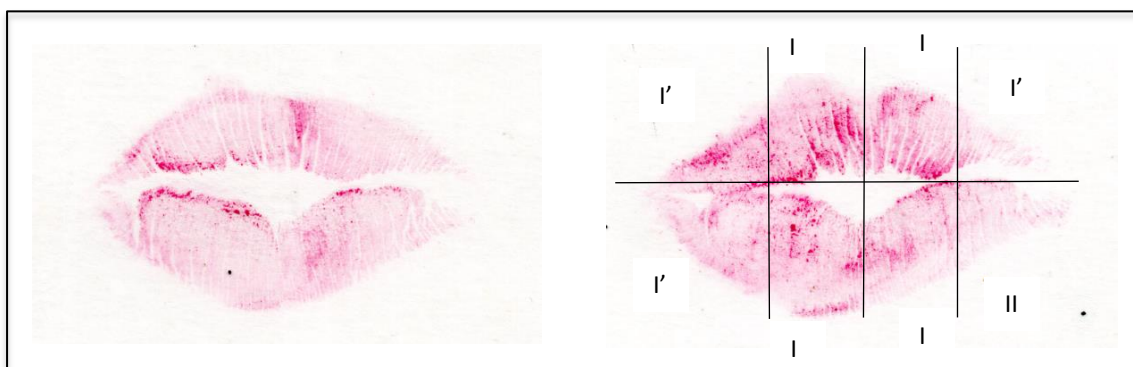


Figure 6. Lip impressions after the 2nd HA filling session.

Studies show that a reduction in lip volume is associated with signs of ageing such as widening of the upper lip skin and a reduction in its thickness, inversion of the vermilion of the lower lip, ptosis of the lip commissure, erasure of the filter, and consequently the appearance of perioral wrinkles^{8,16}. In addition to ageing, genetics, sun exposure and repetitive muscle spasms of the orbicularis oris of the mouth produce angular, radial and vertical lines of the perioral lines¹⁷. Lip augmentation with HA is used to improve the dimensional relationship of the lips with the patient's face, increase the height of the vermilion, soften perioral lines and wrinkles, adding volume and creating projection, as well as reducing excess dental exposure¹⁸, verified in the clinical case reported.

Regarding lip contour, a study involving 200 volunteers showed that lip contour is unique to each individual and does not change over time, concluding that the lip contour pattern can be used for personal identification in the forensic area¹⁹. On the other hand, in the case presented, in addition to volumizing the lips, the HA filler significantly altered the lip contour, showing that performing aesthetic procedures on the lips compromises the reliability of the cheiloscopy method, making it unfeasible to use in these cases of identification by its contour pattern.

For the study of lip prints, the anatomical area to be analyzed is the so-called vermilion zone of the lip, which corresponds to the area of the mucosa with a thin epithelium and a thin layer of keratin, well vascularized and devoid of dermal appendages with few sebaceous glands

that are covered by lines and grooves that determine the lip pattern²⁰. With regard to the design of the sulcular lines, some sextants remained the same as the previous impression. The predominant patterns were complete vertical lines and bifurcated lines, which after filling were classified as incomplete vertical lines. One of the explanations may be related to the presence of HA, since it eliminates some expression lines and attracts water molecules, inducing the formation of the patient's own collagen, allowing local support and hydration of the treated tissue^{11,12}. In the case reported here, there may have been a reduction in the labial furrows due to the effect of HA on the reorganization and integration of the tissue matrix.

On this point, Segui et al. (2000)²¹ state that one should not find exact matches in the absolute dimensions between two lip impressions, since they can derive from the same lip and yet not coincide, either because of the pressure with which they were produced, or because the lip has increased in size due to growth or fat. The change found in the study can also be attributed to the mobility of the lip, which means that the same person produces different impressions depending on the pressure used to record the impression²²⁻²⁴. In addition to the pressure applied, the amount of lipstick used to make the impression is another factor that affects the quality of the lip impression for comparison purposes²⁵.

Another problem related to cheiloscopy analysis is subjectivity, which requires attention to classification and the

collection of lip print information and lip analysis by the same examiner⁴ and that they receive adequate training to acquire the competence and experience necessary to identify the lip print². In this study, the analyses were carried out by the same duly calibrated examiner.

Several studies have recognized the uniqueness of cheiloscopy and, through a systematic review of current literature, the authors concluded that cheiloscopy is an effective, fast and low-cost technique for use in human identification. Its use is limited in cases where there is an advanced state of putrefaction, carbonization or when the labial region has some pathological condition, and there is no evidence of identification in relation to gender or hereditary characteristics²⁶. No studies were found investigating the interference of lip fillers in the method. This study reflects the need for more studies to verify the implication of HA in cheiloscopy analysis and confirm its applicability in the forensic environment.

RESUMO

A queiloscopia é uma técnica de identificação humana que consiste em estudar os lábios e suas características, como a espessura, a disposição da comissura labial, a posição dos sulcos e suas classificações, bem como o registro das impressões produzidas por eles em vários suportes. O aumento dos lábios com preenchedores de ácido hialurônico (AH) se tornou muito popular nos últimos anos, principalmente após inclusão da harmonização facial como especialidade odontológica. O objetivo deste estudo foi verificar se o preenchimento labial com AH tem implicações no estudo queiloscópico, por meio de um relato de caso clínico. Paciente do sexo feminino, 37 anos, leucoderma, participou do estudo. Foi realizado o registro fotográfico e tomadas as medidas de espessura labial, disposição da comissura labial e obtenção das impressões labiais com auxílio de batom, antes do preenchimento labial, 15 dias após aplicação de 1 ml de AH e 15 dias após completos 2 ml de preenchimento com AH. Os resultados do estudo sugerem que o preenchimento labial com AH pode interferir no método queiloscópico, pois houve alteração da arquitetura dos lábios, da disposição da comissura labial, melhorou contorno, arco do cupido e filtro, com mudança significativa na espessura dos lábios superior e inferior de aproximadamente 42% em relação ao volume anterior. Quanto ao padrão dos sulcos labiais, não houve alteração nos desenhos, no entanto, a qualidade da impressão labial foi afetada devido ao efeito produzido pelo AH.

PALAVRAS-CHAVE

Odontologia legal; Ácido Hialurônico; Lábio.

CONCLUSION

The results suggest that lip filling with HA can interfere with the cheiloscopy method, since there was a change in the architecture of the lips, in the arrangement of the labial commissure, improvement in the definition of the contour, cupid's bow and filter, with a significant change in the thickness of the upper and lower lips. As for the pattern of the lip grooves, there was no change in the designs, however, the quality of the lip impression was affected due to the effect produced by the HA. Further research is needed to investigate the influence of lip fillers on the cheiloscopy method and to prove their reliability in forensic practice.

CONFLICTS OF INTEREST

The authors declare that there was no conflict of interest.

FUNDING

The authors declare that this work had no sources of funding.

REFERENCES

1. Prabhu R, Dinkar A, Prabhu V, Rao P. Cheiloscopy: Revisited. *J Forensic Dent Sci.* 2012;4(1):47–52. <https://doi.org/10.4103/0975-1475.99167>.
2. Fonseca GM, Ortíz-Contreras J, Ramírez-Lagos C, López-Lázaro S. Lip print identification: Current perspectives. *J Forensic Leg Med.* 2019;65:32–8. <https://doi.org/10.1016/j.jflm.2019.04.009>.
3. Herrera L, Fernandes CM da S, Serra M da C. Human identification by means of conventional and digital Cheiloscopy: a study of the literature. *Rev Gaúcha Odontol.* 2013;61(1):113–20.
4. Caldas I, Teixeira A, Pérez-Mongiovi D, Afonso A, Magalhães T. Identificação por queilosopia e palatoscopia. Identificação em Medicina Dentária. Imprensa da Universidade de Coimbra; 2016. p. 109–31.
5. Furnari W, Janal MN. Cheiloscopy: Lip Print Inter-rater Reliability. *J Forensic Sci.* 2017;62(3):782–5. <https://doi.org/10.1111/1556-4029.13308>.
6. França GV. Antropologia Médico-legal. Medicina Legal. 10th ed. Guanabara Koogan; 2015. p. 179–81.
7. Yazdanparast T, Samadi A, Hasanzadeh H, Nasrollahi S, Firooz A, Kashani M. Assessment of the efficacy and safety of hyaluronic acid gel injection in the restoration of fullness of the upper lips. *J Cutan Aesthet Surg.* 2017;10(2):101. https://doi.org/10.4103/JCAS.JCAS_115_16.
8. Luthra A. Shaping lips with fillers. *J Cutan Aesthet Surg.* 2015;8(3):139. <https://doi.org/10.4103/0974-2077.167269>.
9. Rohrich RJ, Bartlett EL, Dayan E. Practical Approach and Safety of Hyaluronic Acid Fillers. *Plast Reconstr Surg - Glob Open.* 2019 Jun;7(6):e2172. <https://doi.org/10.1097/GOX.000000000000172>.
10. Sahan A, Tamer F. Four-point injection technique for lip augmentation. *Acta Dermatovenerologica Alp Pannonica Adriat.* 2018 Jun;27(2):71–3. <https://doi.org/10.15570/actaapa.2018.16>.
11. Bertossi D, Sbarbati A, Cerini R, Barillari M, Favero V, Picozzi V, et al. Hyaluronic acid: in vitro and in vivo analysis, biochemical properties and histological and morphological evaluation of injected filler. *Eur J Dermatology.* 2013 Jul;23(4):449–55. <https://doi.org/10.1684/ejd.2013.2059>.
12. Czumbel LM, Farkasdi S, Gede N, Mikó A., Csupor D, Lukács A, et al. Hyaluronic Acid Is an Effective Dermal Filler for Lip Augmentation: A Meta-Analysis. *Front Surg.* 2021;8:1–16. <https://doi.org/10.3389/fsurg.2021.681028>.
13. Utsuno H, Kanoh T, Tadokoro O, Inoue K. Preliminary study of post mortem identification using lip prints. *Forensic Sci Int.* 2005;149(2–3):129–32. <https://doi.org/10.1016/j.forsciint.2004.05.013>.
14. Barros GB, Silva M da, Galvao LCC. Estudo queiloscópico em estudantes do curso de odontologia da Universidade Estadual de Feira de Santana-BA. *Rev Saúde Com.* 2006;2(1):3–11.
15. Tsuchihashi Y. Studies on personal identification by means of lip prints. *Forensic Sci.* 1974;3(C):233–48. [https://doi.org/10.1016/0300-9432\(74\)90034-X](https://doi.org/10.1016/0300-9432(74)90034-X).
16. Bass LS. Injectable Filler Techniques for Facial Rejuvenation, Volumization, and Augmentation. *Facial Plast Surg Clin North Am.* 2015 Nov;23(4):479–88. <https://doi.org/10.1016/j.fsc.2015.07.004>.
17. Sforza C, Grandi G, Binelli M, Dolci C, De Menezes M, Ferrario VF. Age- and sex-related changes in three-dimensional lip morphology. *Forensic Sci Int.* 2010 Jul;200(1–3):182.e1-182.e7. <https://doi.org/10.1016/j.forsciint.2010.04.050>.
18. Pascali M, Quarato D, Carinci F. Filling Procedures for Lip and Perioral Rejuvenation: A Systematic Review. *Rejuvenation Res.* 2018 Dec;21(6):553–9. <https://doi.org/10.1089/rej.2017.1941>.
19. Maloth AK, Dorankula SPR, Pasupula AP. Lip outline: A new paradigm in forensic sciences. *J Forensic Dent Sci.* 2016;8(3):178. <https://doi.org/10.4103/0975-1475.195109>.
20. Sharma P, Saxena S, Rathod V. Cheiloscopy: The study of lip prints in sex identification. *J Forensic Dent Sci.* 2009;1(1):24. <https://doi.org/10.4103/0974-2948.50884>.
21. Seguí MA, Feucht MM, Ponce AC, Pascual FAV. Persistent lipsticks and their lip prints: new hidden evidence at the crime scene. *Forensic Sci Int.* 2000 Jul;112(1):41–7. [https://doi.org/10.1016/S0379-0738\(00\)00173-0](https://doi.org/10.1016/S0379-0738(00)00173-0).
22. Verma Y, Einstein A, Gondhalekar R, Verma A, George J, Chandra S, et al. A study of lip prints and its reliability as a forensic tool. *Natl J Maxillofac Surg.* 2015;6(1):25–30. <https://doi.org/10.4103/0975-5950.168227>.
23. Sharma V, Ingle N, Kaur N, Yadav P. Identification of sex using lip prints: A clinical study. *J Int Soc Prev Community Dent.* 2014;4(6):S173–7. <https://doi.org/10.4103/2231-0762.149030>.
24. Prabhu R, Dinkar A, Prabhu V. Digital method for lip print analysis: A New approach. *J Forensic Dent Sci.* 2013;5(2):96–105. <https://doi.org/10.4103/0975-1475.119772>.
25. El Domiaty MA, Al-gaidi SA, Elayat AA, Safwat MDE, Galal SA. Morphological patterns of lip prints in Saudi Arabia at Almadinah Almonawarah province. *Forensic Sci Int.* 2010 Jul;200(1–3):179.e1-179.e9. <https://doi.org/10.1016/j.forsciint.2010.03.042>.
26. Santos AN dos, Falcão TN, Lima LNC, Vieira TI, Santiago BM. A Queilosopia como técnica de identificação humana: Uma revisão sistemática da literatura. *Res Soc Dev.* 2021 Jul;10(8):e50110817401. <https://doi.org/10.33448/rsd-v10i8.17401>.