

## Revista Brasileira de Odontologia Legal – RBOL

ISSN 2359-3466

<http://www.portalabol.com.br/rbol>



### Forensic Odontology

#### HUMAN IDENTIFICATION ESTABLISHED BY THE ANALYSIS OF FRONTAL SINUS SEEN IN ANTEROPOSTERIOR SKULL RADIOGRAPHS USING THE MENTO-NASO TECHNIQUE – A FORENSIC CASE REPORT.

#### *Identificação humana pela análise do seio frontal em radiografias anteroposteriores com incidência mento-naso em crânio humano – um relato de caso pericial.*

Rhonan Ferreira SILVA<sup>1,2</sup>, Lívia Grazielle RODRIGUES<sup>1</sup>, Scheila MANICA<sup>3</sup>, Raquel Porto Alegre Valente FRANCO<sup>4</sup>, Ademir FRANCO<sup>5</sup>.

1. Department of Dentistry - Forensic Odontology, Federal University of Goiás, Goiás, Brazil.
2. Department of Forensic Odontology, Scientific Police, State of Goiás, Brazil.
3. Centre for Forensic and Legal Medicine and Dentistry, University of Dundee, Scotland, UK.
4. Dentist, Private practice, Curitiba, Brazil.
5. Department of Therapeutic Stomatology, Institute of Dentistry, I. M. Sechenov First Moscow State Medical University, Moscow Russian Federation.

#### Information about the manuscript

Received in: 09 Oct 2018

Accepted in: 10 Nov 2018

#### Corresponding author:

Rhonan Ferreira Silva  
School of Dentistry, Federal University of Goiás –  
Goiânia, Goiás, Brasil.  
Av. Universitária Esquina com 1ª Avenida s/nº  
Setor Leste Universitário, Campus Colemar Natal e Silva  
CEP: 74605-220. Goiânia - Goiás - Brasil.  
E-mail: [rhonansilva@gmail.com](mailto:rhonansilva@gmail.com).

#### ABSTRACT

Introduction: Human identification is a challenging task, especially when the available information detected during the dental autopsy is scarce. In this context, distinctive morphological information may play a valuable role as additional and alternative identifiers. Objective: To report a case of human identification aided by the morphological analysis of the frontal sinus through anteroposterior radiographs of the skull with the mento-naso technique. Material and methods: The body of an edentulous adult male highly decomposed was referred to the local medico-legal institute for identification. The alleged relatives of the victim provided the comparative antemortem data (AM) – consisting of an anteroposterior (AP) skull radiograph taken with mento-naso projection. A postmortem AP radiograph of the deceased was taken in order to reproduce the AM data and to enable a comparative procedure. Results: The morphological information of the frontal sinuses converged between AM and PM radiographs both for metric and non-metric evidences. Conclusion: The analysis of the frontal sinus may be an additional and alternative approach for human identification – especially for edentulous victims.

#### KEYWORDS

Anatomy; Forensic odontology; Frontal sinus; Human identification; Radiology.

#### INTRODUCTION

An increasing trend of violent deaths enlarged the forensic demand for human identifications in medico-legal services in the

last decades. Fingerprint, dental and DNA analyses consist of traditional methods for human identification<sup>1</sup>. However, these methods may not be useful in certain

circumstances, e.g. dental analysis may be hampered in the absence of teeth or dental records, while fingerprint and DNA analyses are hampered when the soft and hard tissues are highly decomposed or completely destroyed. In these cases, alternative approaches are necessary to aid the identification process. The radiographic comparison of the morphological sinuses arises as a potential alternative<sup>1</sup>. The frontal sinus morphology has considerably distinctive traits that can be used effectively for human identification<sup>2</sup>.

Specifically, the morphological information from the frontal sinus can be registered with radiographs of the skull<sup>3</sup>. In these radiographs, the frontal sinus is represented as a radiolucent area that corresponds to a cavity in the skull<sup>4</sup>. In most of the cases, pairs of frontal sinuses are found separated by a median septum in the skull. Additionally, other septa may subdivide the frontal sinus in lobes. This arrangement culminates in a broad variety of morphological combinations that result in different patterns of sinuses among people. Knowing the importance and role of the frontal sinus from human identification purposes is essential especially for dentists and physicians that perform radiographic exams of the skull more often.

Based on the exposed, the present study aims to report a case of positive human identification established through the comparison of morphological traits of frontal sinuses registered in antemortem (AM) and postmortem (PM) anteroposterior (AP) radiographs of the skull using the mento-naso technique.

## CASE REPORT

An adult male body in an advanced stage of decomposition was found floating in a river in the rural area of the state of Goiás, Brazil. Forensic investigations were carried out in the location and, afterwards, the body was sent to the regional department of Legal Medicine in order to determine the cause of death and the identity of the victim.

The necropsy showed no evidence of trauma to the skull, trunk or limbs that would indicate the cause of death. The liquefaction of thoracic viscera prevented the confirmation or exclusion of a possible drowning, so that, the cause of death remained unknown. Moreover, the autopsy of the oral cavity revealed that the victim was edentulous.

Three days after the body recovery, alleged relatives of the victim reported that the body under investigation was of a 71-year-old man and edentulous who went missing for eight days. As the analysis of fingerprints was impossible as the body was in advanced stage of decomposition, the alleged family was advised to search for medical or dental records associated to the missing person. The available information was that the missing person used to wear a pair of full dentures and had an anteroposterior (AP) skull radiograph (taken with the mento-naso projection) taken two months prior to his disappearance (Figure 1).

This radiograph allowed the visualisation of the bilateral frontal sinus which presented further expansion to the left side, median septum and absence of intermediate septa.

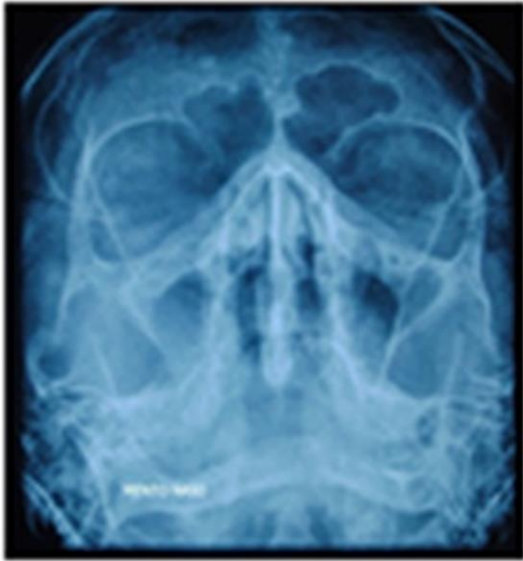


Figure 1 – Antemortem radiograph of the victim.

To perform the radiographic comparison between AM and PM radiographs, the skull of the deceased was positioned and radiographed in AP position with the mento-naso projection in order to obtain the PM radiograph (Figure 2). This allowed the analysis of the morphology of frontal sinus which presented the same anatomical characteristics.

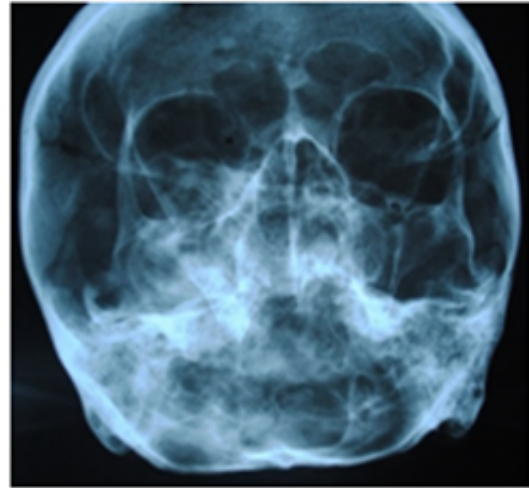

Figure 2 – Postmortem radiograph of the victim.

In addition, Ribeiro's technique<sup>3</sup> was carried out with the purpose of comparison of measurements of standardized distances in the frontal sinus between the two images. According to the author, a baseline is drawn horizontally on the upper limit of both orbit cavities. From that, some measurements were taken by tracing lines delimiting the width (A, B, C and D) and height (E, F, G and H) of different regions of the frontal sinus (Figure 3).

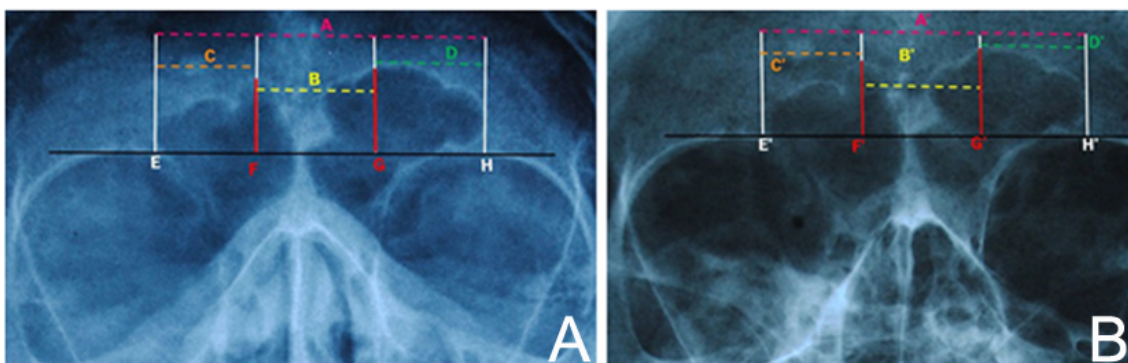


Figure 3 – Ante-mortem (A) and post-mortem (B) radiographs indicating the morphological traits measured according to Ribeiro's technique<sup>3</sup>.

According to the results (Table 1), the absolute values of each measurement were similar and gave strength to the positive identification. Moreover, other

findings such as the anthropological data and the total absence of teeth added to the conclusion of a positive identification and the body was delivered to the family.

Table 1 – Measurements of the frontal sinus taken from the antemortem (AM) and postmortem (PM) radiographs according to Ribeiro's technique<sup>3</sup>

Measurements	AM (mm)	PM (mm)	AM/PM
A	45	60	0.75
B	17	24	0.71
C	13	18	0.72
D	15	18	0.83
F	10	14	0.71
G	12	16	0.75

*The measurements from A to G are indicated in Figure 3.*

## DISCUSSION

The frontal sinuses are cavities present in the frontal bone<sup>4</sup>. The development starts by the age of 2 years and the growth is at a slow pace until puberty, then it accelerates and reaches completion by the age of 20 years. They generally remain stable throughout adult life<sup>5</sup> and present characteristics of uniqueness, immutability and permanence, except in cases of trauma or diseases. The advantages of radiographic analysis of the frontal sinus for human identification are the low cost, fast work and the availability of extra oral x-ray units in medical and odontological clinics for the sake of PM examination. It is important to point out the use of infection control standards to avoid cross infection when using the radiology equipment<sup>6</sup>.

In relation to the techniques used to analyse the frontal sinus, the most common is the direct comparison of sinus anatomy between AM and PM anteroposterior skull radiographs. However, the Ribeiro's technique<sup>3</sup> and the digital image superposition are also largely used. There are some considerations regarding the Ribeiro's technique: the absolute values obtained from AM and PM radiographs are

not always completely equivalent and differences occur because of variations of the skull's position<sup>7</sup> during procedure and use of different models and brands of X-ray units. However, the ratio between absolute values (AM and PM) has correlation which collaborate to the direct comparison of anatomy of the sinus.

The demand for the development of advanced technology in radiology is rising. Particularly, the increase of the use of computed tomography (CT) scans in order to obtain the diagnosis and planning of clinical treatments. Concomitantly, this also increases the potential use of CT scanning for forensic purposes<sup>8,9</sup>. On one hand, some developing countries are not able to afford such technology. On the other hand, the use of conventional X-ray such as the AP radiographs of skull are frequent in hospitals and radiology clinics worldwide. For this reason, experts in human identification must have knowledge about standard radiological techniques used in the forensic field, even though the use of CT scanning in human identification is growing and becoming a reality.

It should be noted that there are certain limitations in the analysis of the frontal sinus patterns for personal

identification. Presence of pathology, growth hormone levels, craniofacial configuration or thickness of the frontal bone can affect the frontal sinus morphology<sup>10</sup>. A comprehensive investigation of the medical history could disclose or discard those issues.

## FINAL CONSIDERATIONS

Frontal sinus is a useful tool for human identification. Forensic dentists should be aware of its importance, particularly, in cases characterized by the lack of dental information.

## RESUMO

**Introdução:** O processo de identificação humana é uma tarefa desafiadora, especialmente quando as informações disponíveis durante o exame cadavérico são escassas. Neste contexto, características morfológicas distintivas podem exercer um papel importante como fontes adicionais e alternativas para a identificação. **Objetivo:** Relatar um caso pericial de identificação humana realizada com o auxílio da análise das características morfológicas do seio frontal em radiografias anteroposteriores do crânio com incidência mento-naso. **Materiais e métodos:** O corpo de um adulto edêntulo em avançado estágio de decomposição foi encaminhado para o instituto médico-legal local visando identificação. Os supostos pais da vítima providenciaram material comparativo antemortem (AM) – o qual consistia de uma radiografia anteroposterior do crânio obtida com incidência mento-naso. Uma radiografia postmortem (PM) anteroposterior foi obtida do cadáver para viabilizar a comparação. **Resultados:** As características morfológicas dos seios frontais da vítima convergiram entre os dados AM e PM tanto para fatores métricos como para não-métricos. **Conclusão:** A análise do seio frontal pode ser uma ferramenta adicional e alternativa para a identificação humana – especialmente em vítimas edêntulas.

## PALAVRAS-CHAVE

Anatomia; Odontologia legal; Seio frontal; Radiologia..

## REFERENCES

1. Gonçalves A, Marcelino J, Prado M, Silva R. Identificação humana utilizando radiografia PA de seios maxilares: relato de caso. *Rev Bras Odont Leg - RBOL*. 2014; 1(1):30-9. <http://dx.doi.org/10.21117/rbol.v1i1.5>.
2. Belaldavar C, Kotrashetti VS, Hallikerimath SR, Kale AD. Assessment of frontal sinus dimensions to determine sexual dimorphism among Indian adults. *J Forensic Dent Sci*. 2014; 6(1):25-30. <http://dx.doi.org/10.4103/0975-1475.127766>.
3. Ribeiro FA. Standardized measurements of radiographic films of the frontal sinuses: an aid to identifying unknown persons. *Ear Nose Throat J*. 2000; 79(1):26-8;30,32-33.
4. Wormald PJ, Hoseman W, Callejas C, Weber RK, Kennedy DW, Citardi MJ, et al. The International frontal sinus anatomy classification (ifac) and classification of the extent of Endoscopic Frontal Sinus Surgery (EFSS). *Int Forum Allergy Rhinol*. 2016; 6(7):677-96. <http://dx.doi.org/10.1002/alr.21738>.
5. Verma S, Mahima VG, Patil K. Radiomorphometric analysis of frontal sinus for sex determination. *J Forensic Dent Sci*. 2014; 6(3):177-82. <http://dx.doi.org/10.4103/0975-1475.137052>.
6. Newcomb T, Bruhn A, Giles B. Mass fatality incidents and the role of the Dental Hygienist: are we prepared? *J Dent Hyg*. 2015; 89(3):143-51.
7. Silva R, Vaz CG, Domiciano M, Franco A, Nunes C, Prado M. Radiographic alterations of the frontal sinus morphology according to variations of the vertical angle in posteroanterior radiographs of the skull. *Acta Scient Health Sci*. 2014; 32(1):113-7. <http://dx.doi.org/10.4025/actascihealthsci.v36i1.20243>.
8. Kim DI, Lee UY, Park SO, Kwak DS, Han SH. Identification using frontal sinus by three-dimensional reconstruction from computed tomography. *J Forensic Sci*. 2013; 58(1):5-12. <http://dx.doi.org/10.1111/j.1556-4029.2012.02185.x>.
9. Beaini TL, Duailibi-Neto EF, Chilvarquer I, Melani RF. Human identification through frontal sinus 3D superimposition: Pilot study with Cone Beam Computer Tomography. *J Forensic Leg Med*. 2015; 36:63-9. <http://dx.doi.org/10.1016/j.jflm.2015.09.003>.
10. David MP, Saxena R. Use of frontal sinus and nasal septum patterns as an aid in personal identification: A digital radiographic pilot study. *J Forensic Dent Sci*. 2010; 2(2):77-80. <http://dx.doi.org/10.4103/0975-1475.81286>.